



Pierre FAJADET

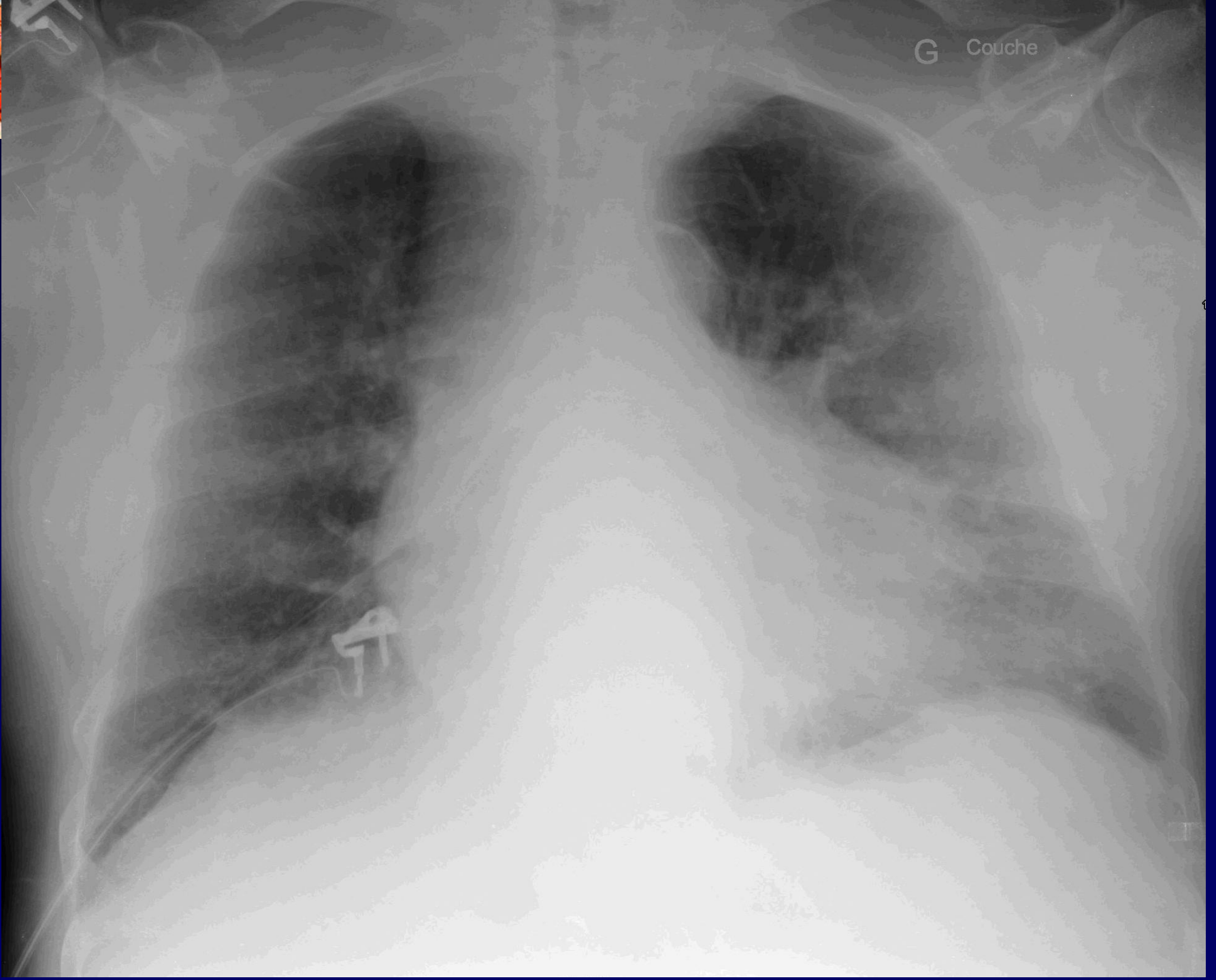Homme de 70 ans

C1: BPCO

Dyspnée majorée

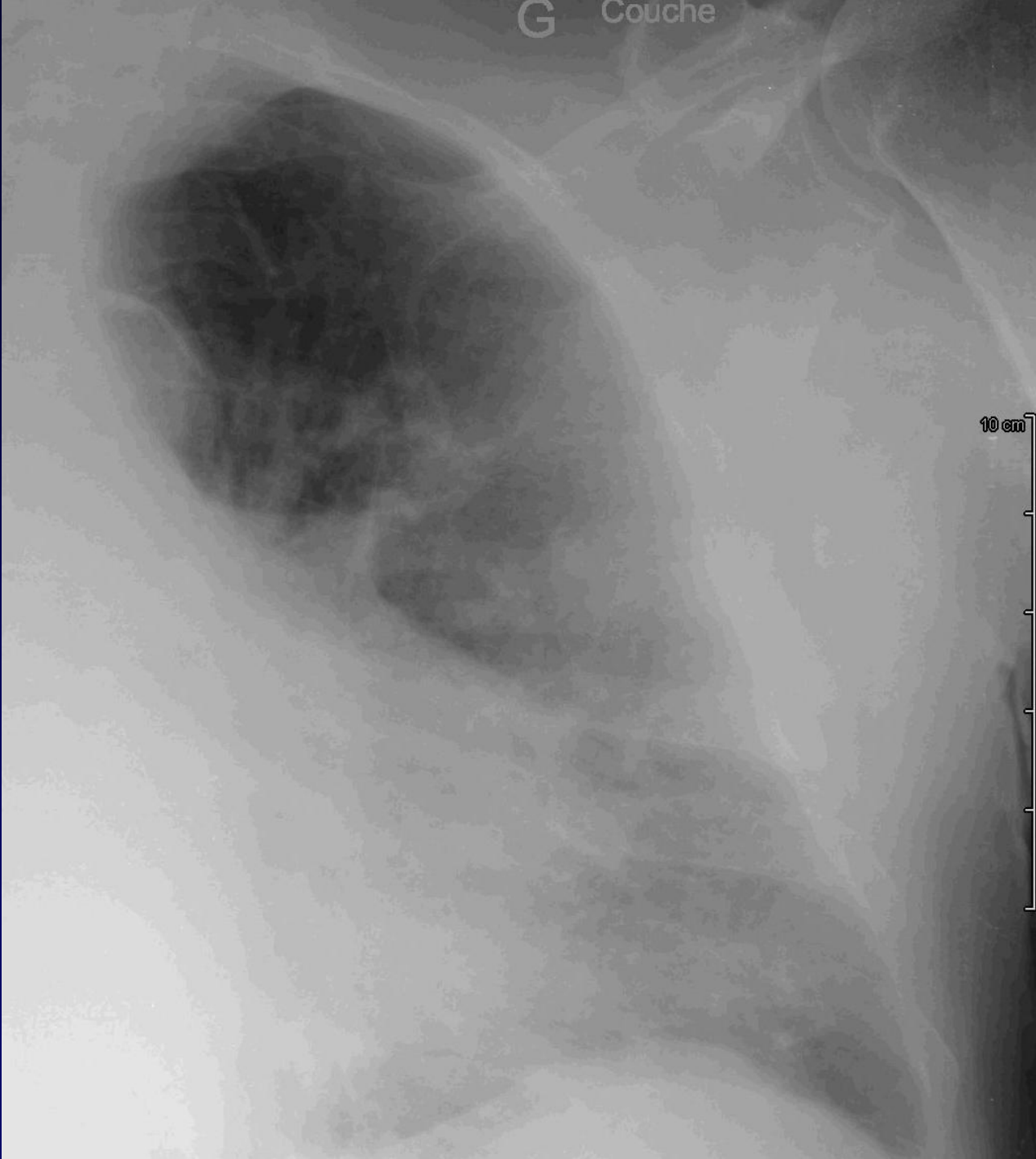
Pas de signe infectieux net

G Couche



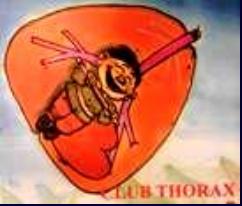

G Couche



10 cm

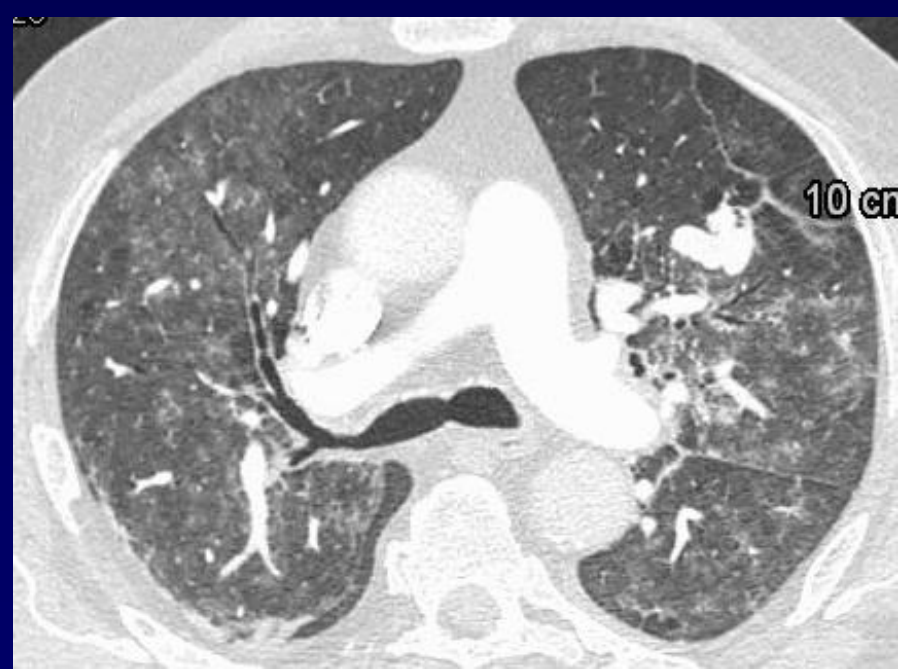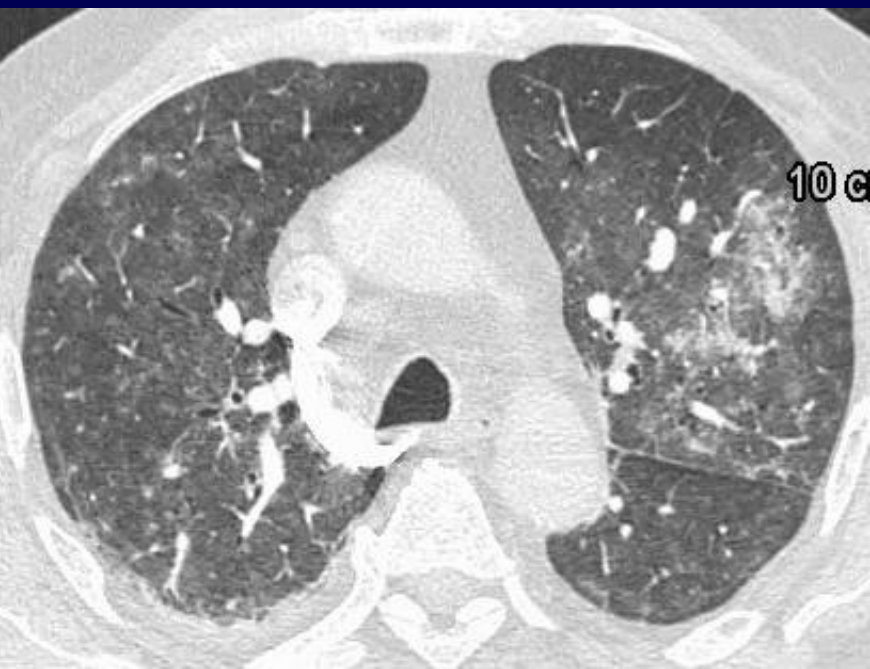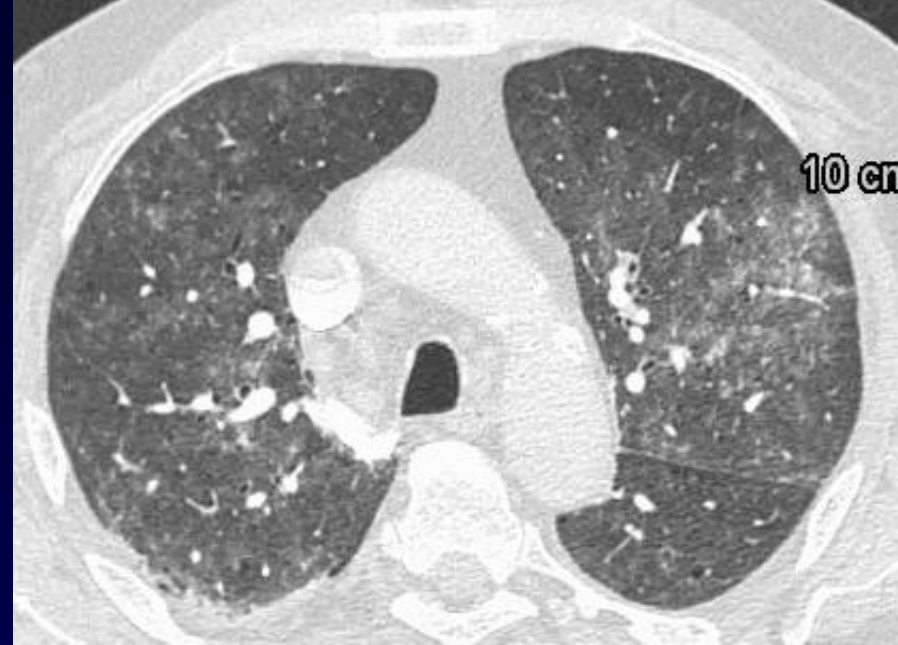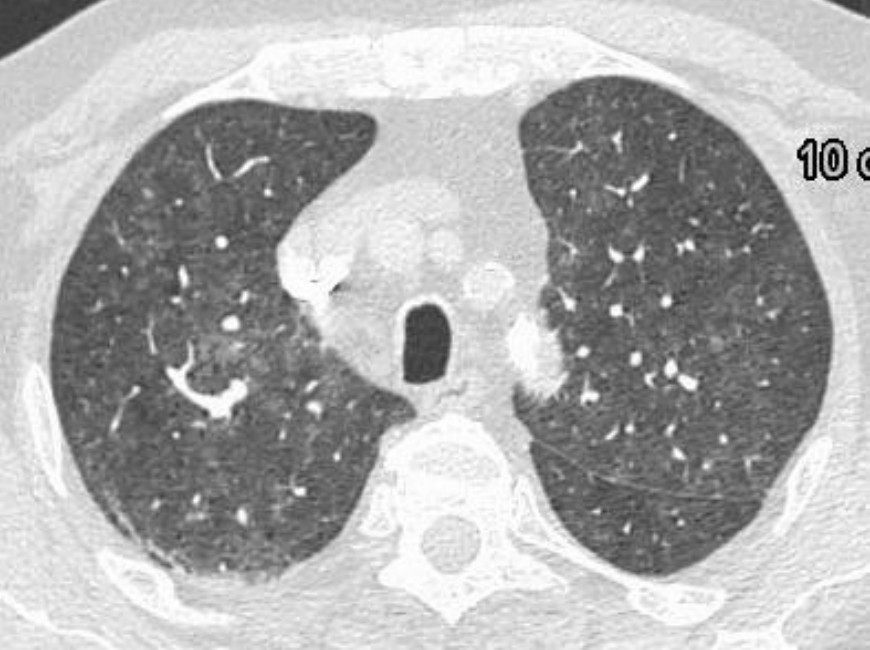


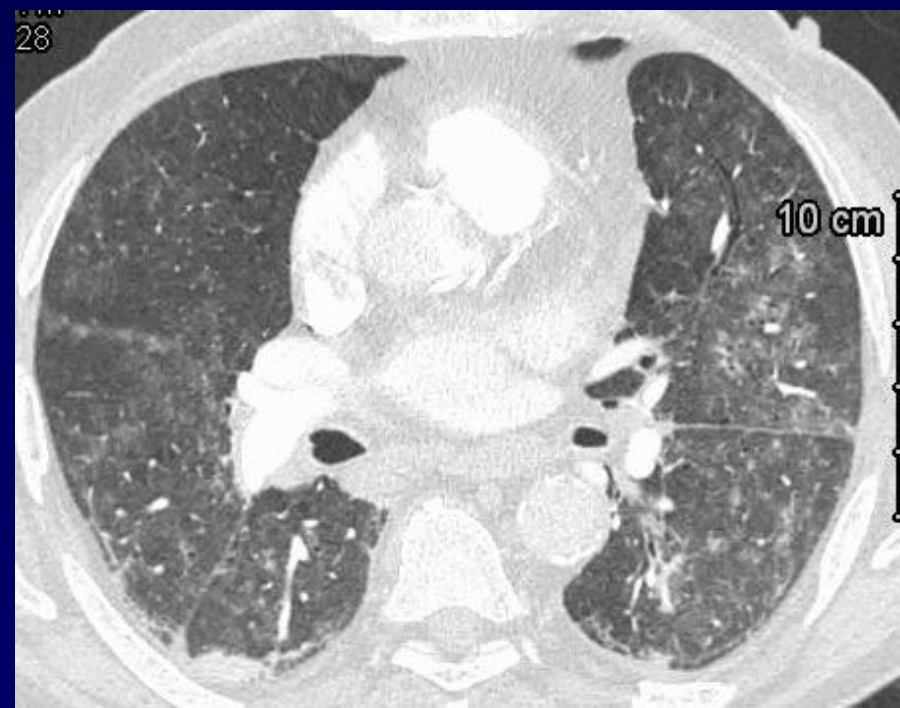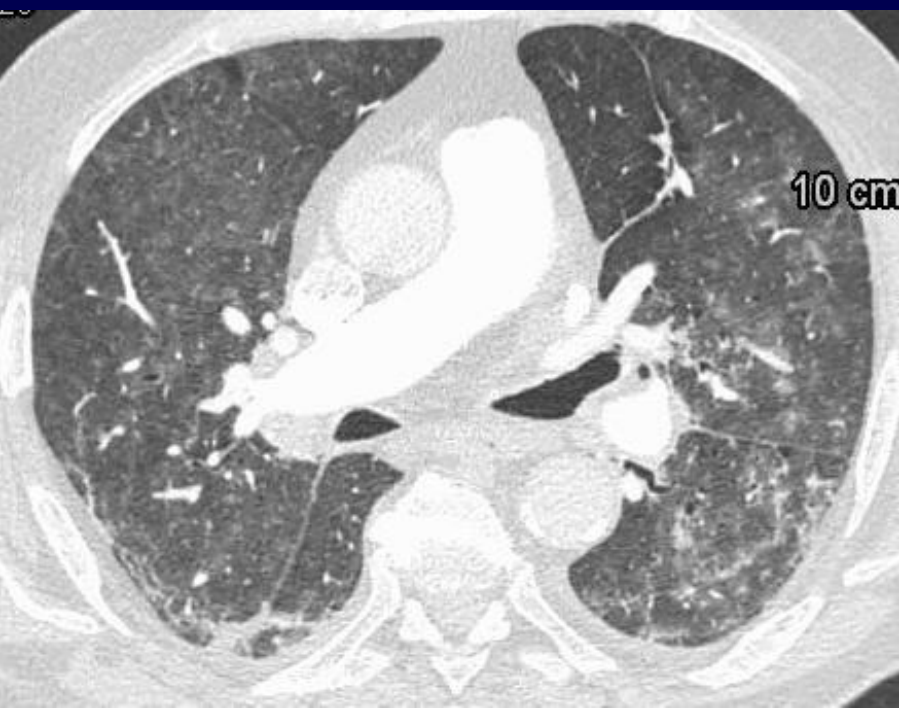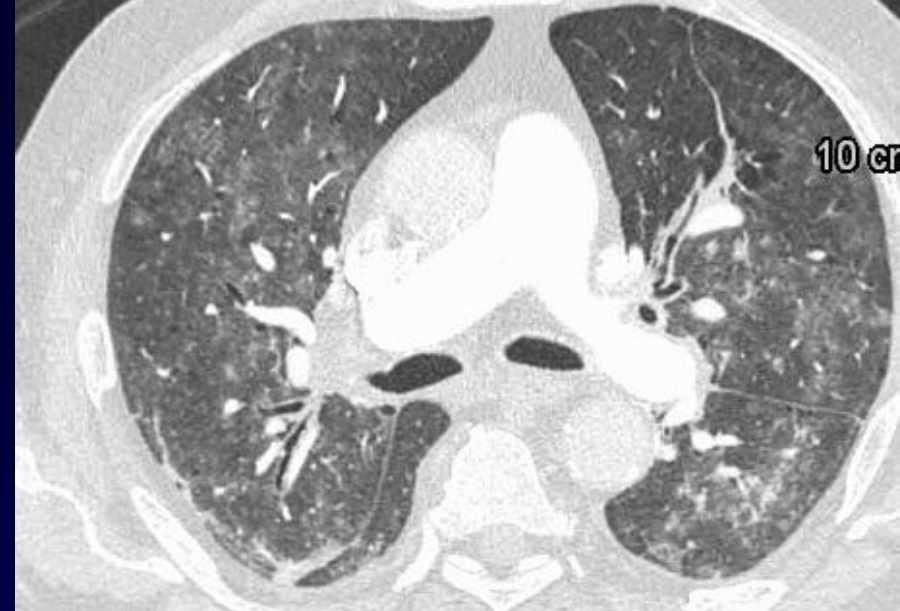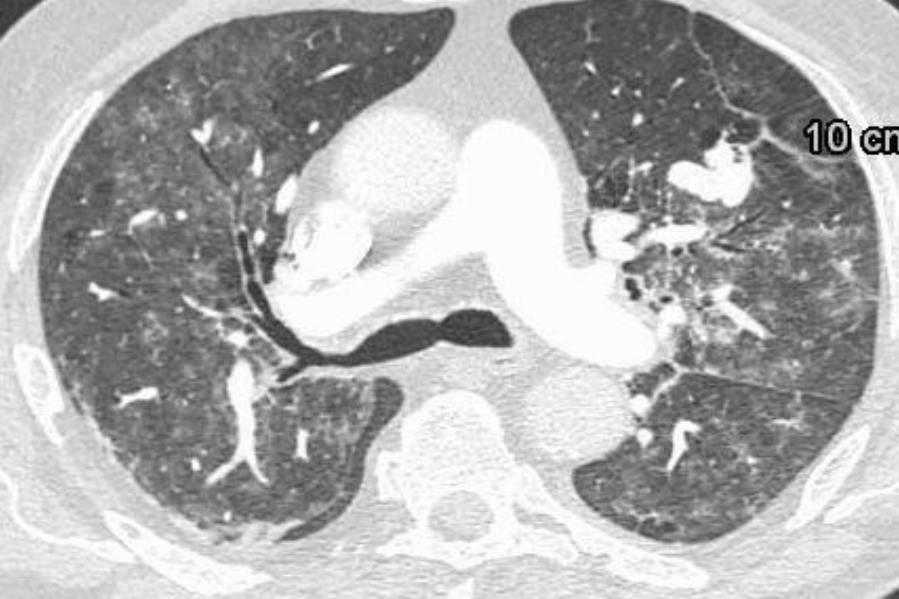


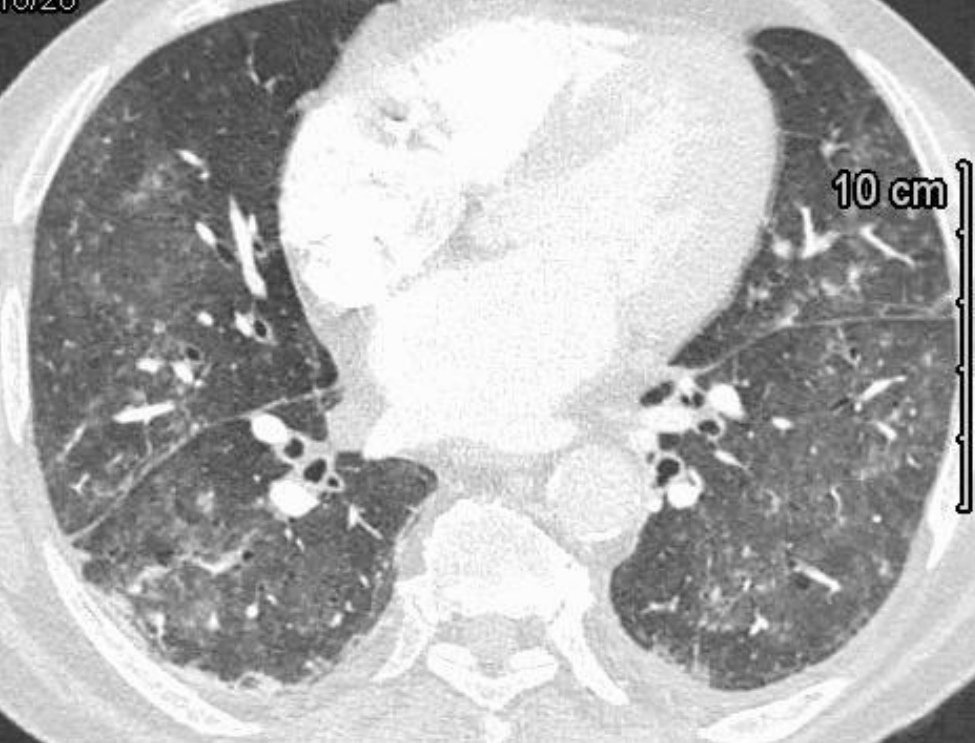EFR: VEMS 1,70 l (N = 2,15),

Tiffeneau = 64%

Gazométrie: PO₂ = 65, PCO₂ = 30

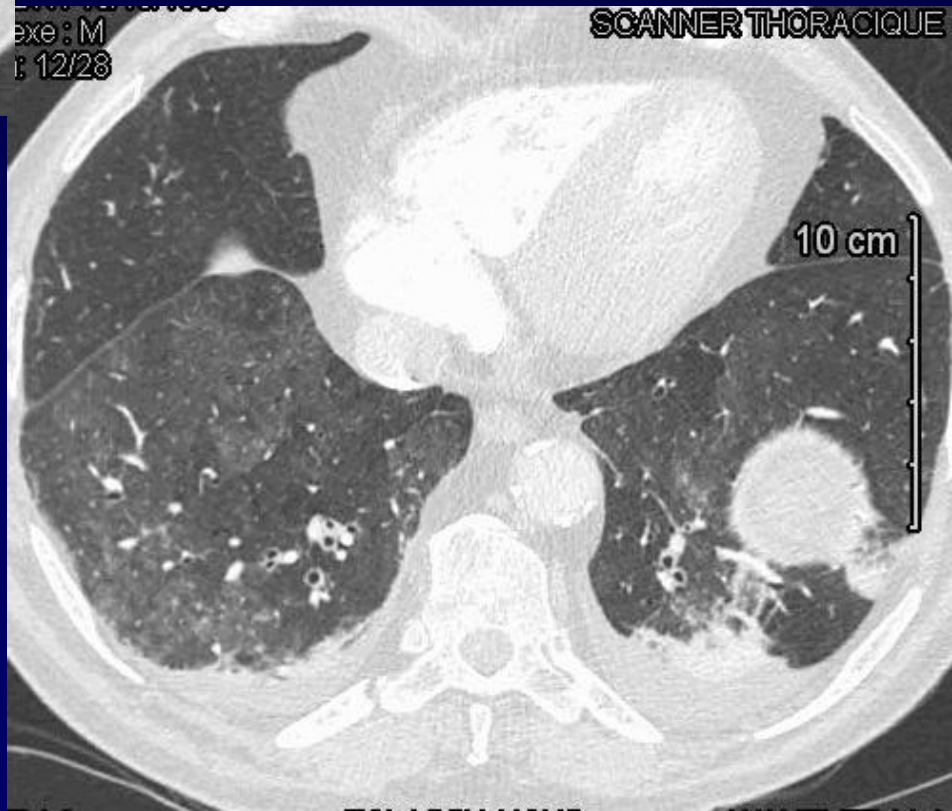






Sex: M
Date: 12/28

SCANNER THORACIQUE

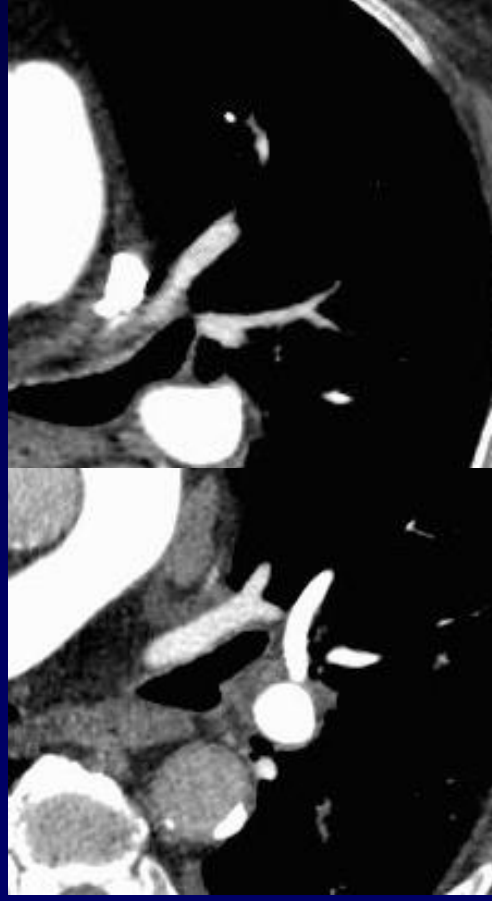
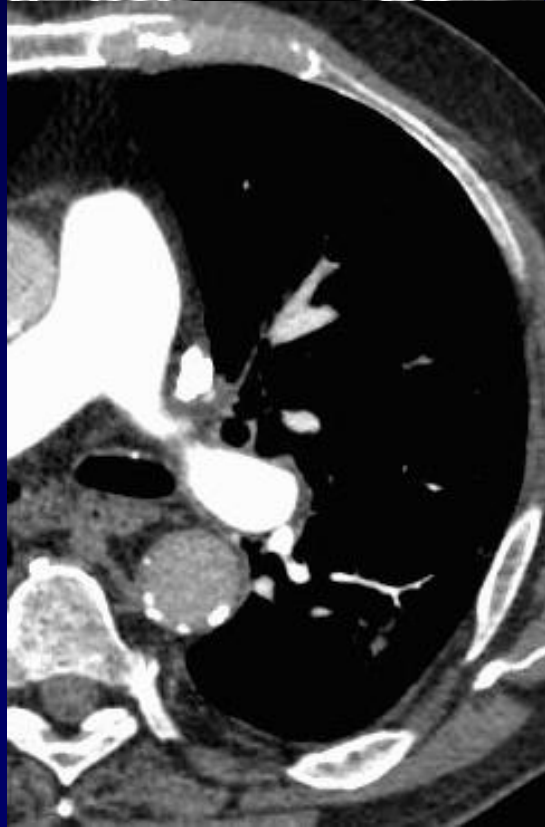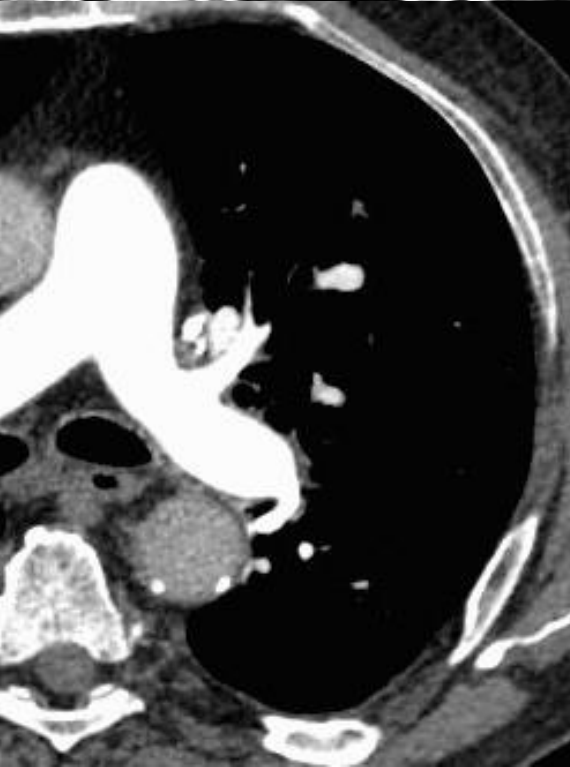
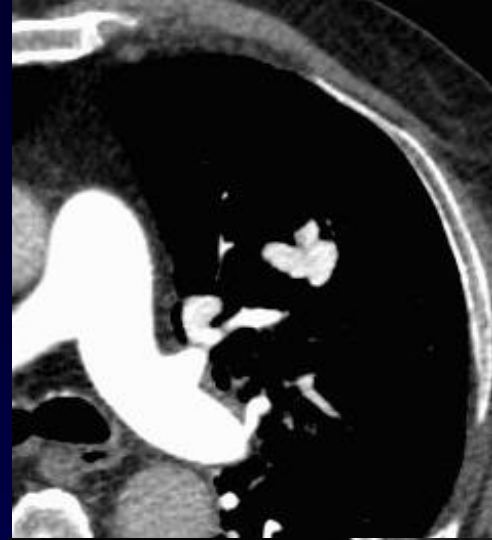
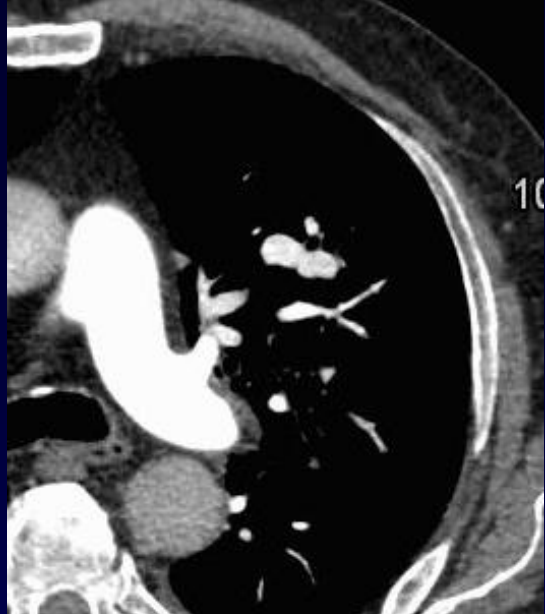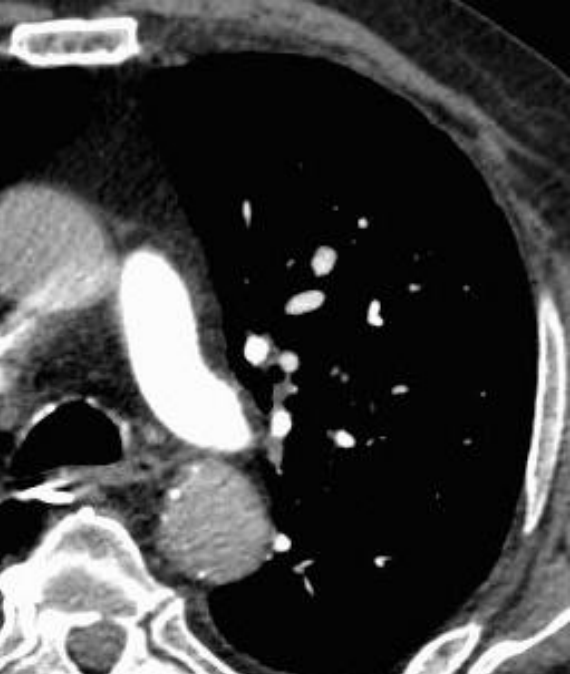


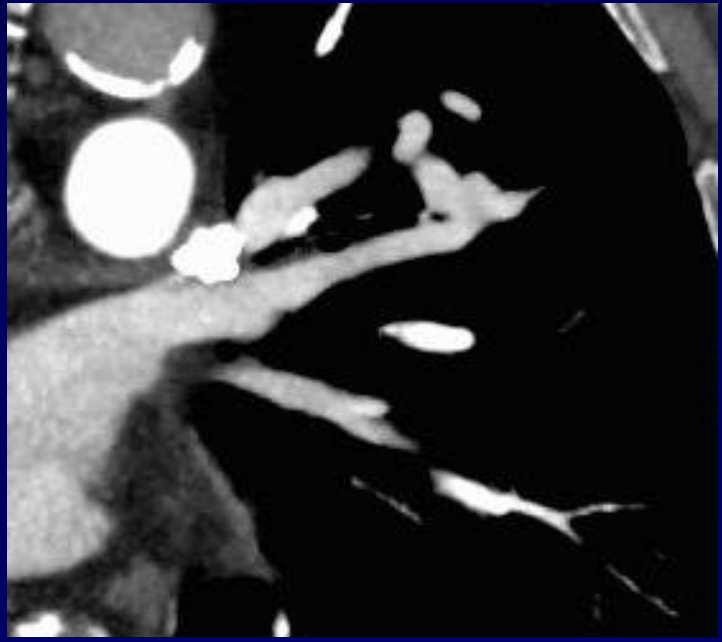
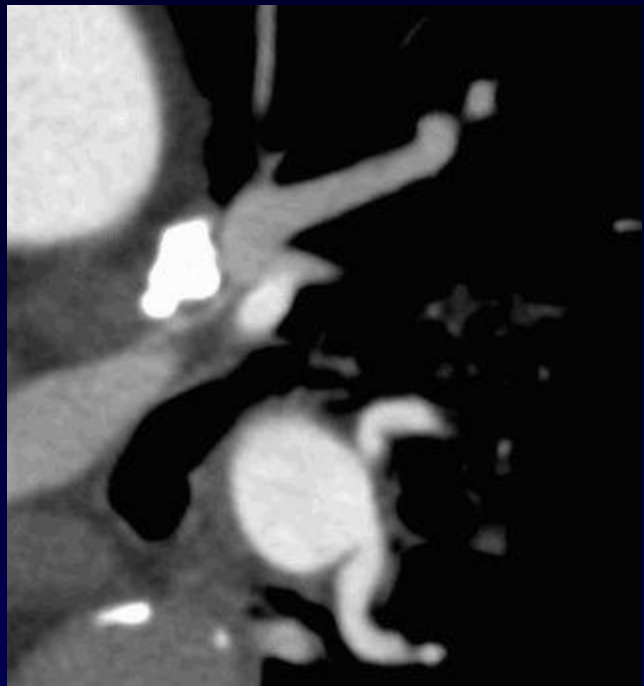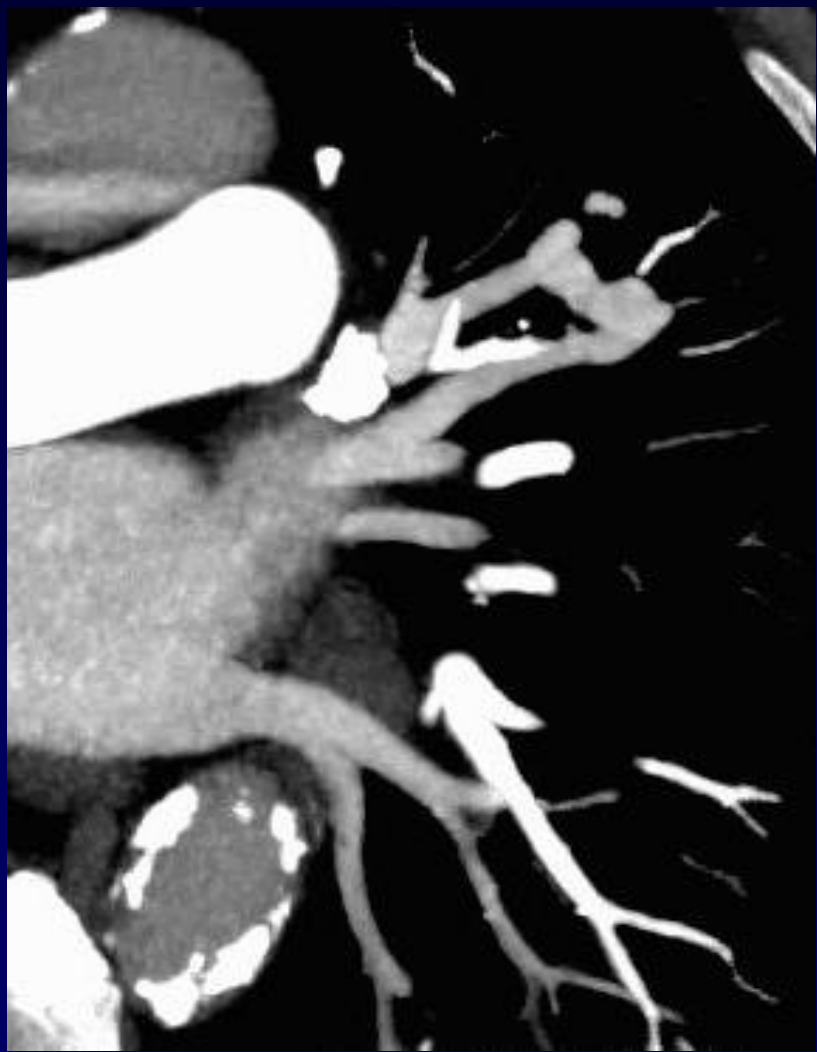


Diagnostic ?

Patient sous cordarone

Mais aussi ...?







Diagnostic ?



Diagnostic

Pneumopathie à la cordarone

Anastomose veino-veineuse